

CS-018

Minimally Invasive Surgery for Necrotizing Fasciitis

John R. Crew, MD¹, Randell Varilla, RN, MSN¹, Thomas Allandale Rocas III, RN, BSN, CWCN¹, Dmitri Debabov, PhD², Russell Hoon² and Ramin (Ron) Najafi, PhD²

¹ Wound Care Center, Seton Medical Center, 1900 Sullivan Avenue, Daly City, CA 94015 ² NovaBay Pharmaceuticals, Inc. 5980 Horton Street, Suite 550, Emeryville, CA 94608

Abstract

Background. Necrotizing fasciitis (NF), commonly known as flesh-eating disease, is an infection of the deeper layers of skin and subcutaneous tissues, easily spreading across the fascial plane within the subcutaneous tissue. NF is a quickly progressing and severe disease of sudden onset and is treated immediately with massive debridement and intravenous antibiotics. Despite the aggressive treatment mortality rate and loss of limbs remain high (10 - 70%). This is because the disease is frozen in the inflammatory phase II of wound healing. While bacteria are killed by antibiotics, remaining bacterial toxins and superantigens produce massive inflammatory response.

Objectives. To evaluate a new treatment for NF.

Method. The new techniques include 1) Antibiotic therapy 2) Small incision in the affected area 3) Irrigation with pure 0.01% hypochlorous acid* and vacuuming using negative pressure wound therapy (NPWT).

Results. A 51-year old female with a history of a minor abrasion from a fall in the parking lot, fever, arm edema and tenderness and then sudden shock with unobtainable blood pressure; a 41-year old female with swelling and erythema of the lower abdomen and right upper thigh; a 29-year old male with fever, pain, abscess of right hip and buttocks and soft tissue emphysema shown by X-ray; a 23-year old with an acute infection and abscess of his right finger and hand; and a 54-year old male with chills, fever, swelling and pain of scrotum and perineum, were diagnosed with NF or Fournier Gangrene. After incision, drainage and debridement pure 0.01% hypochlorous acid* with NPWT was successfully used to treat these patients, resulting in no deaths or amputations and complete healing. It was shown in vitro that pure 0.01% hypochlorous acid* inactivates bacterial toxins.

Conclusion. Based on these clinical cases, our data indicate that pure 0.01% hypochlorous acid*, used with NPWT, should be considered the new treatment regimen for treating NF.

*NeutroPhase®

Introduction

There are 4 phases of normal wound healing: (I) coagulation, (II) inflammation, (III) tissue formation, and then (IV) tissue re-modeling¹. Necrotizing fasciitis (NF) occurs when the wound healing has halted in phase II due to bacterial toxins causing severe inflammation. NF is a disease that can be devastating when untreated. Type I NF is classified as a polymicrobial infection, whereas Type II NF is classified as a monomicrobial infection. NF is caused by many types of bacteria, including but not limited to Group A *Streptococcus* [*Streptococcus pyogenes*], Group B *Streptococcus* [*Streptococcus agalactiae*], *Staphylococcus aureus*, *Vibrio vulnificus*, *Clostridium perfringens*, and *Bacteroides fragilis*. Immunocompromised people are more likely to develop these infections². With aggressive treatment of antibiotics and surgery, there's still a high chance of mortality and limb amputation.

Materials & Methods

The patient was put on a series of antibiotics to treat for any cultured bacteria. Small incisions were made in the affected area with minimal debridement. Any necrotic subcutaneous tissue can be surgically suctioned out. Black foam (KCI) was sized and placed in the wound. A separate inflow tube (IV extension with port) was placed on and through the black foam. The adhesive drape was attached and placed over the entire area including the black foam. The area around the tubing was sealed with Stomadhese. The VAC was then turned on and adjusted from 50-125 mm Hg suction. 0.01% hypochlorous acid* (5-10 mL) was instilled via syringe through the inlet-port into the wound bed with the vacuum on (Fig. 1).

Results

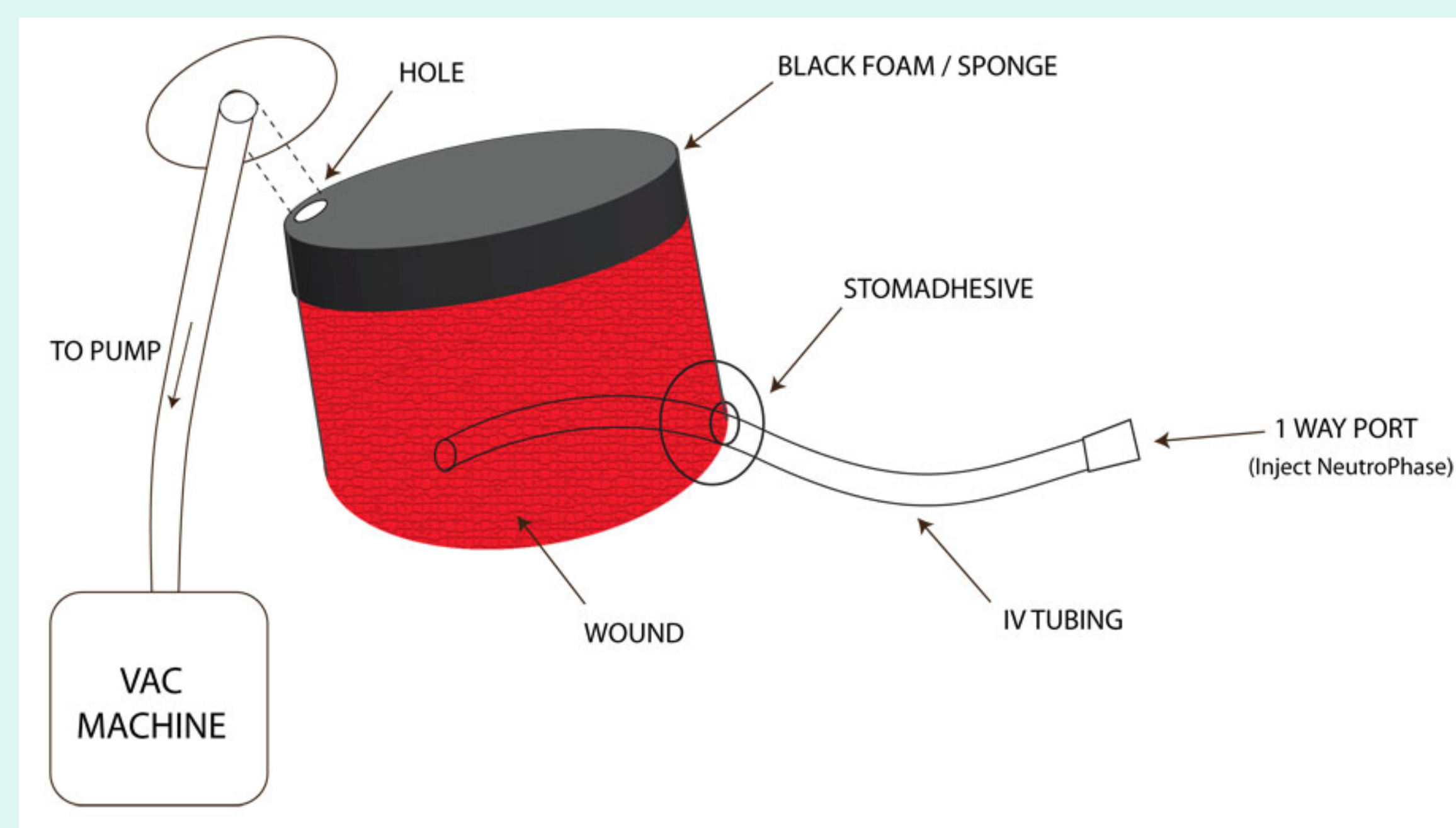


Figure 1. A line diagram of the equipment for NPWT with adjunctive NeutroPhase® irrigation.¹

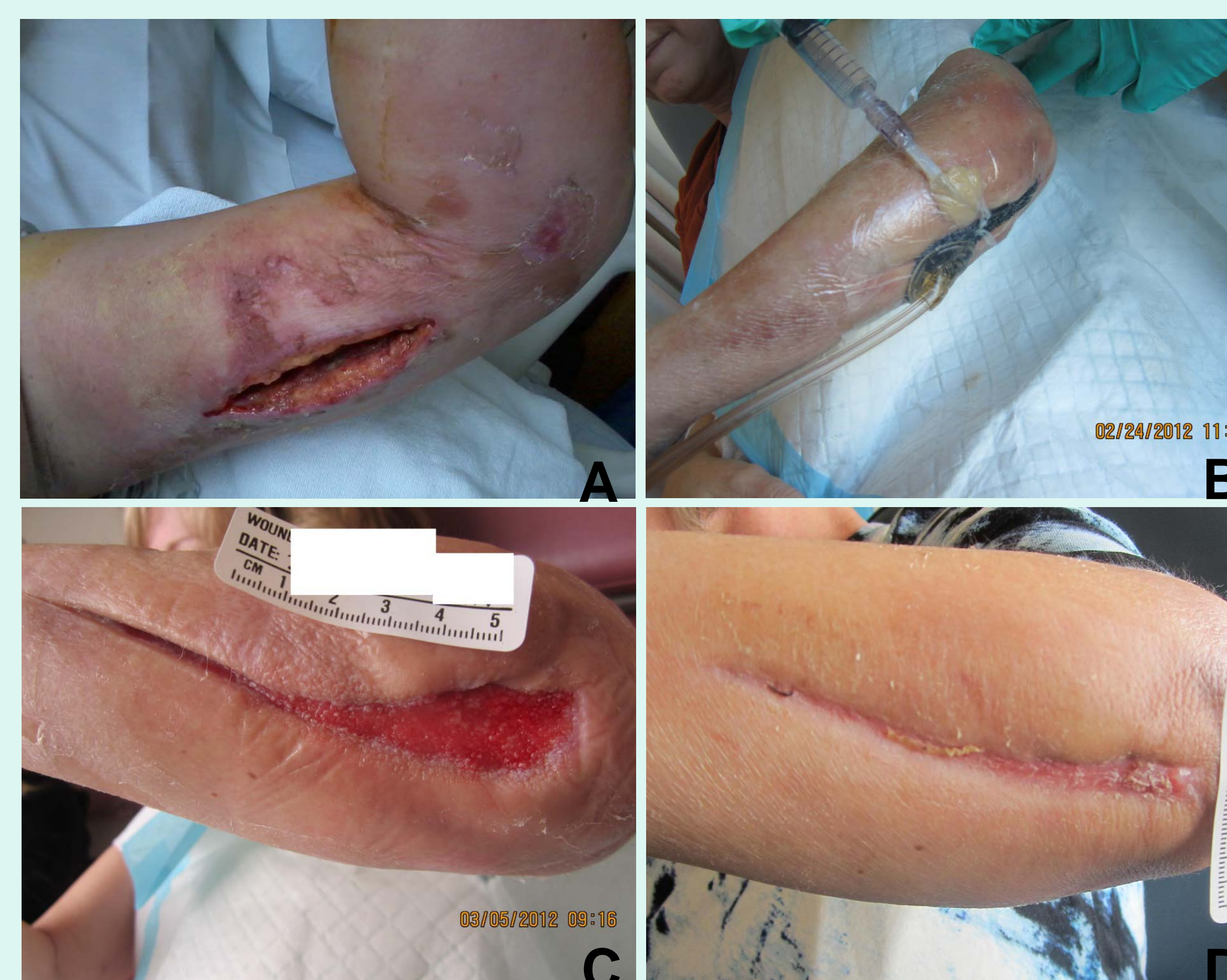

Figure 2. A: 51-year-old patient with NF in the arm. B: NeutroPhase® was instilled along with limited incision and only open drainage into a sponge. C: The wound quickly changed to regenerative stage and D: healed.

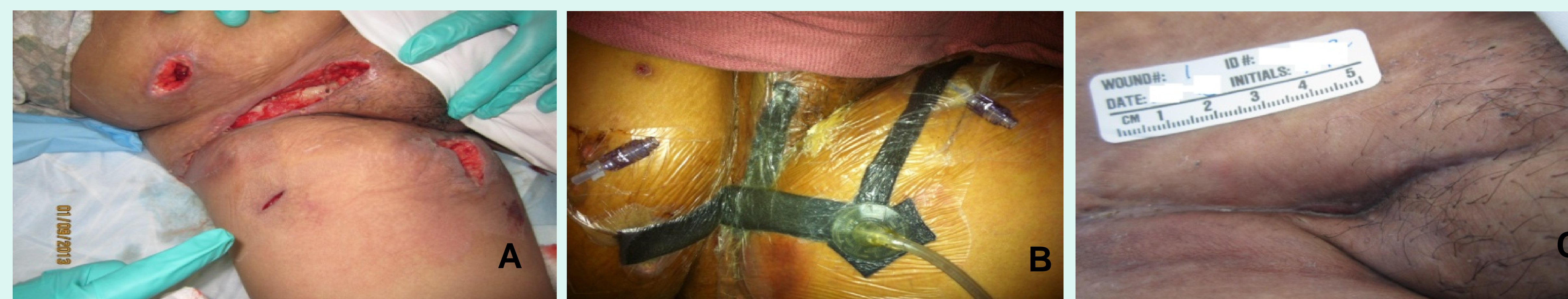

Figure 3. A: 41-year-old patient with NF of the lower abdomen and right upper thigh. Multiple small incisions were used without removing infected fascia, just suctioning out necrotic subcutaneous tissue. B: Instill VAC irrigation was conducted through multiple ports. C: The result was far less scarring with less pain and more rapid healing.

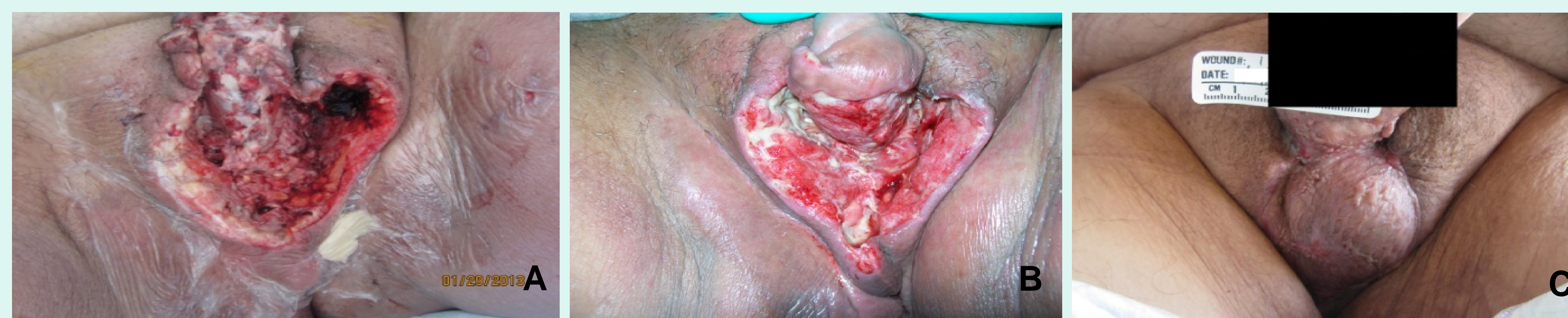

Figure 4. A: 54-year-old patient with abrupt onset of Fournier's gangrene. B: Immediate incision and drainage was performed removing the necrotic skin of the scrotum and penile base followed by instill vac with NeutroPhase® C: Within 2 weeks the thigh stored testicles and cord were surgically freed and eventually healed within one month with a split-thickness skin graft.

Discussion

The aggressive NF treatment starts with antibiotic therapy and then results in a full debridement of all necrotic tissue. However, removing the bacteria and the tissues does not remove any of the toxins that threatens to halt the healing process. Laboratory studies have shown that hypochlorous acid in solution not only has anti-microbial activity, disrupts biofilms, penetrates microbial cells, spore walls and amoeba cysts, but it has been shown that pure hypochlorous acid also rapidly inactivates *S. aureus* and *S. pyogenes* toxins³. Because of this in vitro evidence, we interpret that introducing hypochlorous acid cleanses the wound of toxins allowing the next phase of wound healing to proceed.

These cases suggest that it is unnecessary to be too aggressive especially with the debridement. Small incisions and minimal debridement with the help of surgical suction will allow for quicker recovery and less pain. Over the last 4 years, at least 7 other patients were found with the diagnosis of NF in medical records at Seton Medical Center. They were treated with the standard therapy and 2 died, 1 had amputation and 3 survived. This fits with the expected outcome from the literature⁴. In comparison, 7 NF patients treated with our new therapeutic algorithm resulted in no deaths and no limb amputations. Two of these patients had toxic shock and both recovered, although one was intubated for 16 days in a coma before complete recovery.

Conclusions

- Release of bacterial superantigens and of cellular toxins from damaged cells increases the toxicity. This puts the patient into a critical state which requires incision and drainage
- Based on these clinical cases, our data indicate that pure 0.01% hypochlorous acid*, used with NPWT, should be considered the new treatment regimen for treating NF
- 7 necrotizing fasciitis patients treated with our new therapeutic algorithm resulted in no deaths and no limb amputations, compared to 7 patients treated in the same medical center over the last 4 years with the standard therapy resulting in 2 deaths and one amputation.

*NeutroPhase®

Disclaimer: NeutroPhase® is a solution of pure 0.01% hypochlorous acid (as a preservative) in normal saline, and manufactured by NovaBay Pharmaceuticals Inc. NeutroPhase® is a 510-(k) cleared product for wound cleansing only. Reductions in microbial growth in the NeutroPhase® solution have not been shown to correlate with reductions in infections in patients, as clinical studies to evaluate reductions in infections have not been performed.

References

¹Quinn, J.V. (1998). *Tissue Adhesives in Wound Care*. Hamilton, Ont. B.C. Decker, Inc. Electronic book.
²Kotrappa KS, Bansal RS, Amin NM. Necrotizing fasciitis. *Am Fam Physician*. 1996;53:1691-1697.
³Crew JR, Varilla A, Rocas III TA, Abdul Rani S, and Debabov D. 2013. Treatment of acute necrotizing fasciitis using negative pressure wound therapy (NPWT) and adjunctive NeutroPhase® irrigation under the foam. *Wounds*. 2013;25: 272-277
⁴Rajput A, Waseem, Samad A, Khanzada TW, Shaikh GM, Channa GA. Mortality in necrotizing fasciitis. *J Ayub Med Coll Abbottaba*. 2008; 20:96-98.