

Conquering Chronic Non-Healing Wounds with Pure Hypochlorous Acid

John R. Crew, MD¹, Randell Varilla, RN, MSN¹, Thomas Allandale Rocas III, RN, BSN, CWCN¹, Dmitri Debabov, PhD², Suriani Abdul Rani, MS², Lu Wang, PhD², Ramin Najafi, PhD², and Mark Anderson, PhD²

¹ Wound Care Center, Seton Medical Center, 1900 Sullivan Avenue, Daly City, CA 94015 ² NovaBay Pharmaceuticals, Inc.5980 Horton Street, Suite 550, Emeryville, CA 94608

Abstract

Chronic non-healing wounds, such as venous stasis ulcers, diabetic ulcers, and pressure ulcers are serious unmet medical needs that affect a patient's morbidity and mortality. Systemically administered antibiotics do not effectively decrease the level of bacteria or the associated biofilm in a chronic granulating wound. Topical antiseptics have a long history of use, such as sodium hypochlorite (Dakin's solution), hydrogen peroxide, acetic acid and povidone-iodine that remain in widespread use today. However used at typical concentrations, these antiseptics can actually impede wound healing¹. We have more than 30 clinical case studies where we used NeutroPhase[®] with and without negative pressure wound therapy (NPWT) to assist in wound healing. Common pathogens observed in these chronic wounds include *Staphylococcus* including MRSA, *Pseudomonas*, *Enterobacter*, *Stenotrophomonas*, and *Serratia* spp. In our *in vitro* experiment, we also show that 0.01% pure HOCl is more active than sodium hypochlorite against *S. aureus* by a zone of inhibition assay. HOCl has been described as being 80-100 times more potent as a germicide than the hypochlorite anion (OCI⁻; high pH). NeutroPhase[®] is pure 0.01% hypochlorous acid (i.e. >97% relative molar distribution of active chlorine species as HOCl) in a 0.9% saline solution at pH 4-5 and NovaBay has an FDA cleared 510(k) for wound care. Our data show that there is a clear utility for the use of NeutroPhase[®] as a key agent in wound care and to address this serious unmet medical need.

Introduction

Chronic non-healing wounds have many factors contributing to the impairment of healing such as the presence of foreign bodies, tissue maceration, ischemia, infection, and biofilms. The clinical picture can be further complicated by systemic factors such as diabetes, malnutrition, renal disease, and advanced age. Therefore, chronic non-healing wounds are a clinical problem that for some is a serious unmet medical need. Pure 0.01% HOCl (NeutroPhase[®]) has been shown in a well-established chronic granulating wound rat model² to be an effective topical antimicrobial and to have a potential application as an antimicrobial wound irrigation. NeutroPhase[®] is a 510(k) cleared self-preserved preparation of HOCl that has been shown to inactivate *P. aeruginosa*, *E. coli*, *S. aureus*, *C. albicans* and *A. niger* in solution. Using Sorbact as the wound mesh dressing in combination with NeutroPhase[®] as the irrigation solution assists in wound healing. NeutroPhase[®] is not toxic to living tissue.

Materials & Methods

For the Zone of inhibition assay, 100 uL of the formulations were applied every 15 min and removed before next application. Up to 4 treatments were completed over 1 hr. The clear parts represent "kill zones". A combination of NeutroPhase[®] (0.01% HOCl) as the irrigation solution and Sorbact (Abigo Medical AB, Askim, Sweden) as the wound mesh dressing was used to treat patients with chronic non-healing wounds. Before treatment, the wound area was cleansed and the wound was debrided, then the skin was dried. Then Sorbact mesh was sized and placed in the wound. A Blake drain was placed on and in the Sorbact mesh. The adhesive drape was attached and placed over the entire area including the Sorbact mesh. The area around the tubing was sealed with Stomadhesive. The tubing was connected to a three-way stopcock and a one-way valve was added. The VAC was then turned on and adjusted from 50 mm to 125 mm suction. The pre-determined amount of NeutroPhase[®] was injected through the three-way stopcock and allowed to stay in the wound for 15 minutes before it was vacuumed out. This was subsequently changed to a separate inflow tube (IV tubing) and irrigated while the VAC was kept on.

Results




Figure 1. Antimicrobial activity comparison of NeutroPhase[®] vs Microcyn (sodium hypochlorite) gel formulations in Zone of Inhibition assay against *S. aureus* ATCC 29213. (I) One treatment was applied. (II) Two treatments were applied. (III) Three treatments were applied. (IV) Four treatments were applied. Formulations were applied every 15 min and removed before next application.

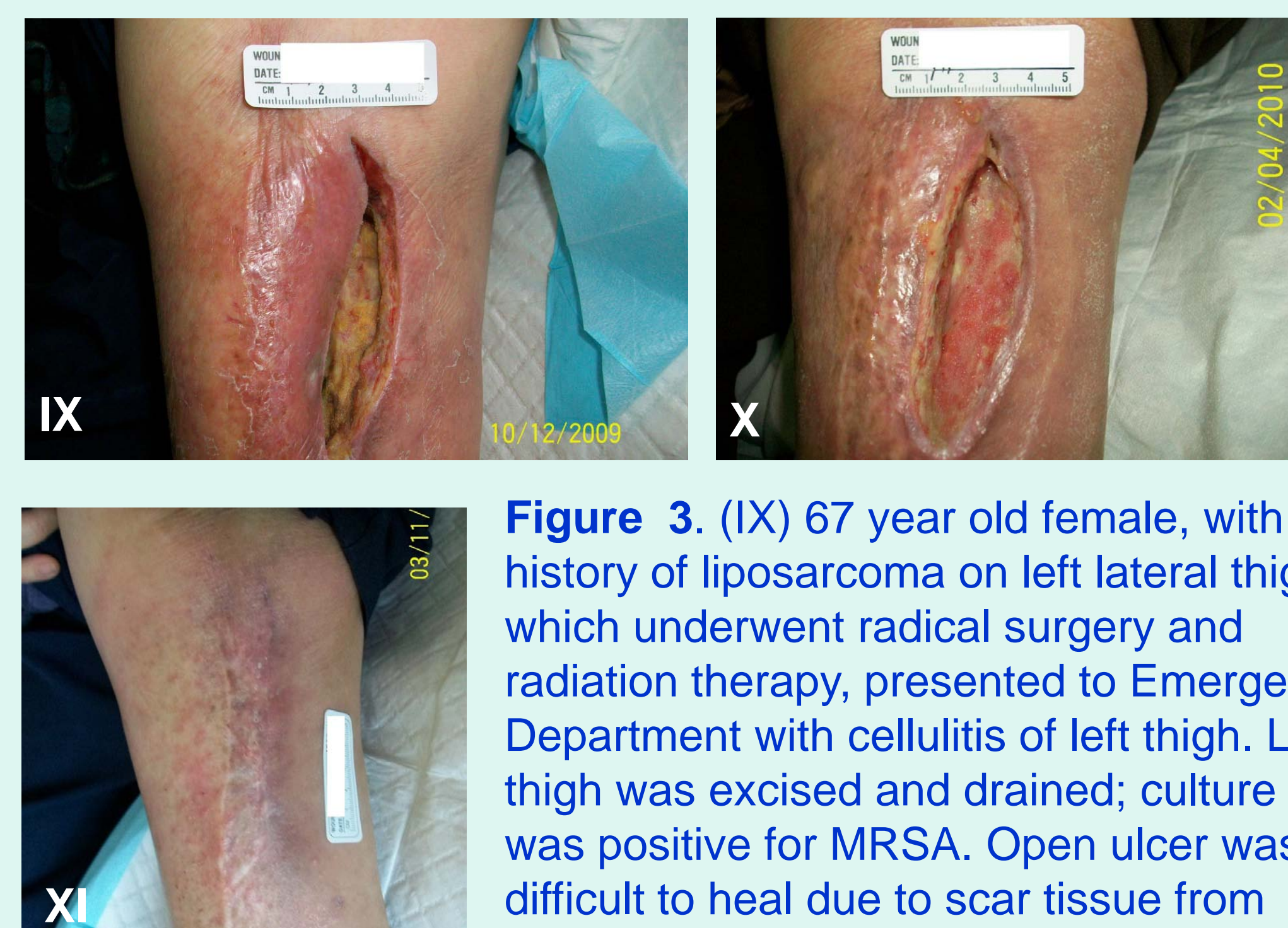

Figure 3. (IX) 67 year old female, with history of liposarcoma on left lateral thigh which underwent radical surgery and radiation therapy, presented to Emergency Department with cellulitis of left thigh. Left thigh was excised and drained; culture taken was positive for MRSA. Open ulcer was difficult to heal due to scar tissue from radiation therapy and MRSA infection. (X) With serial debridement of non-viable tissue and negative pressure wound therapy with HOCl 0.01% instill, wound is now healing evidenced by granulation tissue formation filling in the cavity. (XI) When adequate granulation was achieved and no sign and symptoms of infection, plastic surgery was consulted for flap closure of the wound.

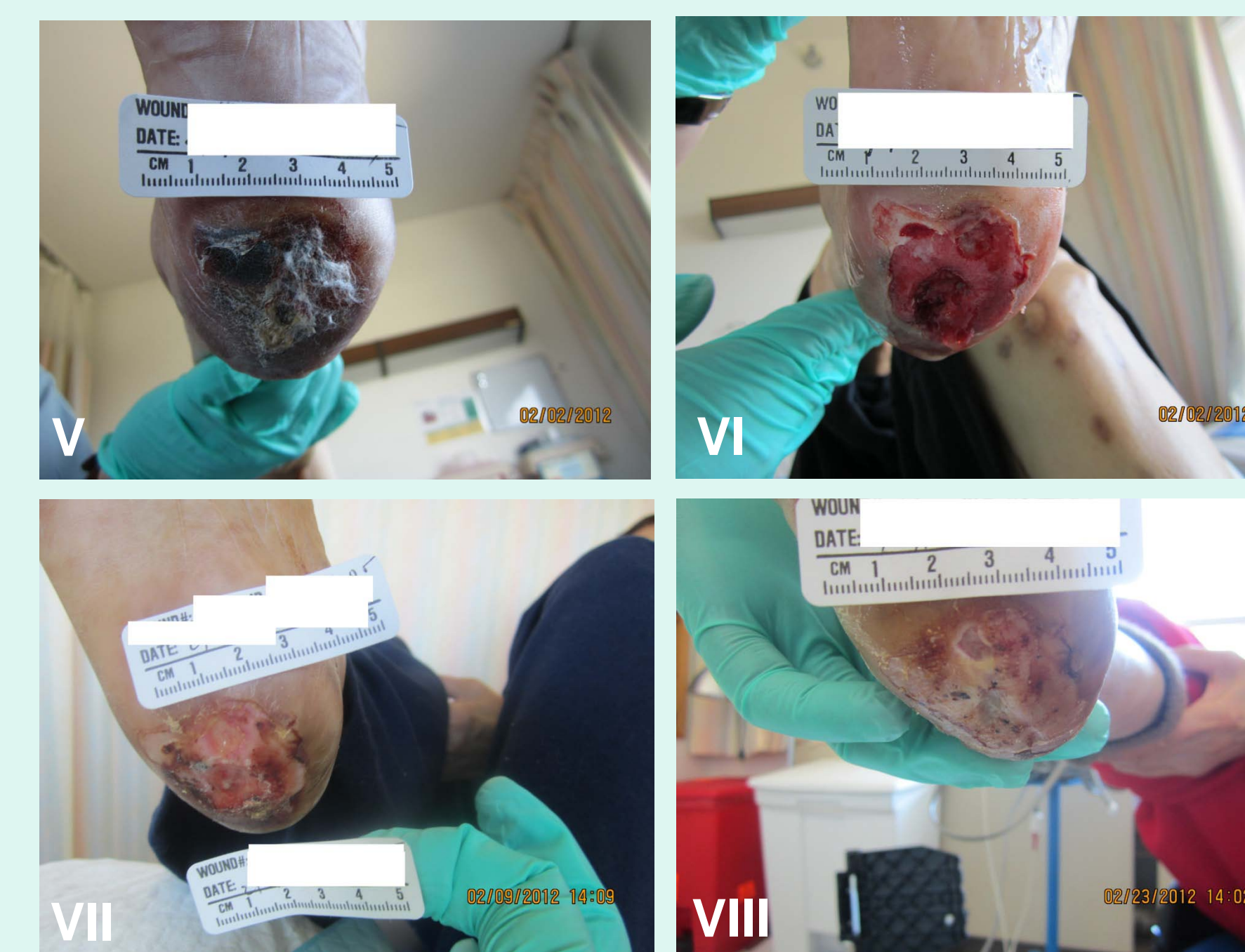

Figure 2. (V) 75 year old female with DM II, End-Stage renal disease presents to wound center with chronic ulcer on the right foot. (VI) Wound post-debridement. (VII) 1 week post-debridement. (VIII) Week 2 of treatment: Patient continues to heal and is now ready for biological skin equivalent to be applied.

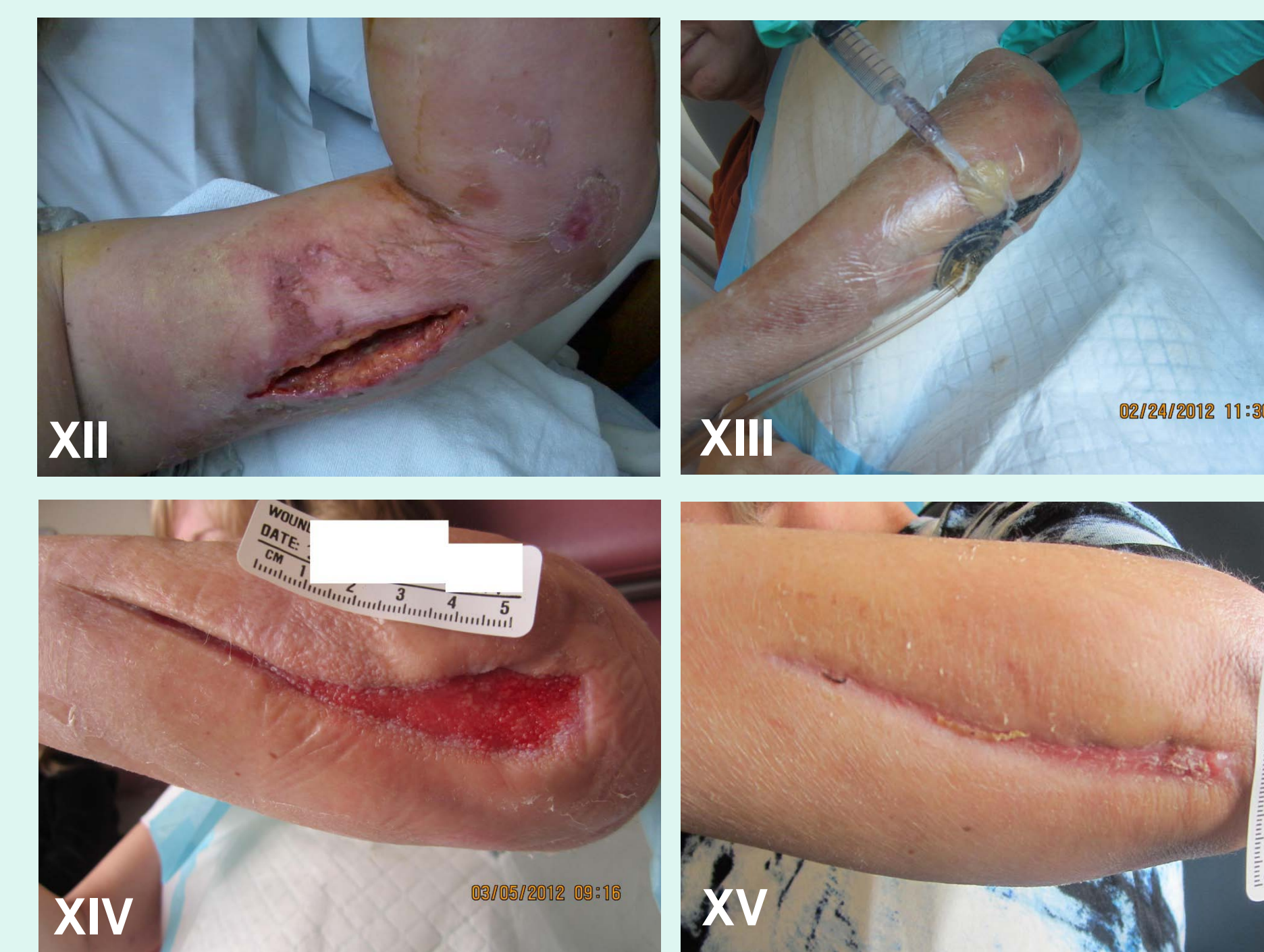

Figure 4. (XII, XIII, XIV, XV) This 51 y/o fell bruising left arm in a parking lot. Three days later arm flared up with streptococcal cellulitis and fasciitis. She went into shock and was admitted to ICU. Incision and Drainage (I and D) one day later followed by repeat lower arm I and D with VAC and instillation of NeutroPhase[®] three times a day. Repeat extension of surgery in forearm. Discharged on VAC and instillation at home 3 1/2 weeks later, now @ 5 weeks upper arm healed and lower arm @ 90% with biological graft in place. No positive cultures obtained, just gram stain streptococcus found.

Discussion

Chronic non-healing wounds have many factors contributing to the impairment of healing such as the presence of foreign bodies, tissue maceration, ischemia, infection, pressure and biofilm. The clinical picture can be further complicated by systemic factors such as diabetes, malnutrition, renal disease, and advanced age. Therefore chronic non-healing wounds impact the patient's morbidity and are a serious unmet medical need. Our studies using Sorbact as the wound mesh dressing in combination with NeutroPhase[®] as the self-preserved irrigation solution assisted in wound healing. NeutroPhase[®] is not toxic to living tissues. Sorbact is a hydrophobic mesh that traps bacteria yet decreases maceration of the adjacent skin next to the wound. Appropriate wound care remains essential with debridement, offloading, antibiotics and appropriate follow up care in the outpatient setting. The treatment can be maximized with the use of negative pressure wound treatment (NPWT) as well by the instillation irrigation and aspiration twice daily with NeutroPhase[®]. In this treatment with the appropriate instillation procedure we used Sorbact mesh as the sponge which does not leave macerating fluids on the skin. Overall this simplifies the vacuum instillation procedure significantly.

Conclusions

- NeutroPhase[®] formulation shows greater antimicrobial activity than Microcyn formulation in the Zone of Inhibition assay against *S. aureus*.
- The results demonstrate that NeutroPhase[®] is an important irrigation solution in treatment of chronic non-healing wounds.
- Sorbact helps reduce tissue maceration.
- NeutroPhase[®] in combination with Sorbact as the wound mesh dressing utilizing negative pressure wound therapy assists in wound healing.
- These case studies show NeutroPhase[®] in combination with Sorbact[®] has the potential to be a very effective wound care product for use in managing difficult to heal wounds.

Disclaimer: NeutroPhase is a 510k cleared product for wound cleansing only and we are claiming only antibacterial activity in solution

References

- 1 Vile G.F., Rothwell L.A., Kettle A.J. Initiation of rapid, P53-dependent growth arrest in cultured human skin fibroblasts by reactive chlorine species. *Arch. Biochem. Biophys.* 2000;377:122-128.
- 2 Robson, M.C.; Payne, W.G.; F.; Mentis.; Ahafii, S.M.; Culverhouse, S.; Wang, L.; Khosrovi, B.; Najafi, R.; Cooper, D.; Bassiri, M. *Journal of Burns and Wounds* 2001;6:80-90